

Management Profile Among Keratoconus – A Retrospective Study

Nayan Gupta^{1*},  Astha Mishra¹,  and Shankar Mehra¹ 

^{1,2}Chitkara School of Health Sciences, Chitkara University, Punjab, India

³Director and Consultant Optometrist, Spectra + Optometry Clinic, Gujarat, India

*nayan.gupta@chitkara.edu.in (Corresponding Author)

ARTICLE INFORMATION

Keywords:

Keratoconus, RGP lenses, Corneal topography, Eye care

ABSTRACT

Purpose: To report the profile management options of the Keratoconus patients who attended in the tertiary eye care center in the year 2021 and to analyze the practice patterns that are considered to be ideal in the management of Keratoconus.

Methods: The data were collected retrospectively and this was a cross-sectional study. The data collected for all patients attending a tertiary eye hospital in the year July 2021 were reviewed and data were collected on the patient demographics, chief complaints, associated clinical conditions, visual acuity, corneal signs of Keratoconus, corneal topography data, and the management with contact lens; type of contact lens prescribed and the contact lens visual acuity was assessed along with others parameters of the contact lens measurement were considered. Descriptive statistics were used to describe the profile of the patients and understand the severity of Keratoconus and the parameters of the contact lenses selected.

Results: There was a total of 31 patients who were diagnosed with bilateral Keratoconus based on the clinical signs of Keratoconus and corneal topography. The mean age was 20.1+6.86. The association with eye rubbing/VKC was found in 25.8% of the total population. The majority of the patients were managed with RGP lenses.

DOI: [10.15415/jmrh.2022.82005](https://doi.org/10.15415/jmrh.2022.82005)



1. Introduction

Keratoconus is an ectatic condition of the cornea in which the cornea becomes thin and irregular. This abnormal shape prevents the light entering the eye from being focused correctly on the retina and causes distortion of vision (Pavlatos et al., 2020). In this condition, genetic factors play an important role (Mathan et al., 2020). The predisposing factors for keratoconus are allergic diseases such as asthma, syndromes like Down's syndrome, and connective tissue disorders such as Marfan's disease (Barbara et al., 2019). It affects up to one in 1,000 people and is more common in people of Asian heritage. It is usually diagnosed in teenagers and young people (Olivo-Payne et al., 2019). It is an asymptomatic condition in the initial stage but with the progression, the visual impairment might increase from mild to severe due to increasing the irregularity of the cornea. This results from myopic astigmatic refractive error as well as corneal scarring (Shehata et al., 2020). Slit lamp examination is the most important initial clinical investigation to rule out the clinical signs of this ectatic condition. The common signs include iron deposition clinically known as Fleischer's ring,

fine vertical lines in the Descemet's membrane referred to as Vogt's Striae, and corneal scarring (Assadpour et al., 2020). Coma is one of the associated optical aberrations with this ectatic condition (Gustafsson et al., 2020). Keratoconus condition may be divided in to three stages:

- *Stage-1 (Early stage):* this stage is usually correctable with soft contact lenses or spectacles. These patients may gain the attention of the ophthalmologist if progressive myopic astigmatism develops, particularly with steeper average keratometric values or topographic readings. As the disease progresses, it is often increasingly difficult to refract the patient to a crisp and clear visual acuity with soft contact lenses or spectacles.
- *Stage-2 (Intermediate stage):* in this stage patients usually experience vision loss that is no longer correctable with soft contact lenses or spectacles. Toric soft lenses often help with correcting some of astigmatism; however, the increasing irregularity of astigmatism may call for rigid gas permeable lenses to achieve a truly crisp vision.
- *Stage-3 (Advanced stage):* in this stage contact lens wear becomes increasingly difficult and often uncomfortable

due to the steepness of the cornea and difficulty in fitting the lenses. Contact lens intolerance is a common indication for corneal transplantation at this stage (Salem & Solodovnikov, 2019; Toprak et al., 2019).

The assessment of keratoconus is done based on slit lamp examination signs and topographical signs. As it progresses slit lamp signs like corneal thinning, ectasia, Fleischer's ring, Vogt's striae, and scarring are seen (Mahmoud et al., 2018). Topographical signs like an asymmetric bow tie with a skewed radial axis. In early keratoconus, typical topography signs are present (Fan et al., 2018). Computerized Corneal topography (CCT) techniques using curvature-based analysis and newer forms of elevation-based tomography appear to be the most sensitive methods for detecting early keratoconus (Athreya, 2018). Management of keratoconus in the early stages, spectacles or soft contact lenses may be used to correct vision. As the cornea becomes thinner and steeper, rigid gas permeable (RGP) contact lenses are often required to correct vision more adequately (Patil et al., 2020). In very advanced cases, where contact lenses fail to improve vision, a corneal transplant may be needed. Changes caused by keratoconus can take many years to develop. For this reason, we monitor those with the condition even after a corneal transplant, eyeglasses or contact lenses are often still needed to correct vision (Şengör et al., 2020). Today contact lens correction for keratoconus is NOT synonymous with rigid corneal lenses. There are numerous options available to the contact lens specialist that can provide significant vision improvement for patients with keratoconus.

For example, RGPCLs have superiority for improving corneal irregularities and decreasing higher-order aberrations. However, it is difficult for some patients to tolerate these lenses (Saraç et al., 2019). HCLs have a rigid central part with a soft peripheral skirt, and they are designed for both to reduce discomfort and to increase visual acuity. However, they have higher complication rates when compared to other types of lenses (Otten et al., 2018). Scleral and mini-scleral contact lenses (MSCLs) have advantages for patients with more irregular corneas; they improve comfort and visual acuity and delay the need for keratoplasty in advanced keratoconic eyes (Efron et al., 2018). The different insertion and removal technique and their care regimen of them are their disadvantages (Rubinfeld et al., 2019). Corneal cross-linking (CXL) is a procedure that alters the biomechanical properties of the corneal collagens by using ultraviolet A (UVA) and riboflavin (vitamin B2). It has been used in the treatment of corneal ectatic disorders including progressive keratoconus, pellucid marginal degeneration, and post-refractive corneal ectasia for years (Lim & Lim, 2020).

It has been revealed by numerous studies that, after CXL procedure, cornea flattens and the maximum keratometry value decreases significantly in keratoconic eyes (Chan, 2020; Lim & Lim, 2020).

2. Methods

This was a retrospective study conducted, Medical records of all patients seen at a tertiary eye hospital in the year July 2021 were reviewed and data were collected on the patient demographics, Chief complaints, Associated clinical conditions, Visual acuity, Refraction, Corneal signs of keratoconus, Corneal topography data, Severity of keratoconus, Management (spectacle, CL or surgery), Type of lens prescribed, Visual acuity with contact lens, Average wearing time for contact lenses and Visual outcome of the treatment. All the patients were diagnosed with keratoconus based on clinical signs and/or topographical signs (Roongpoovapatr et al., 2020). Visual Acuity was recorded with Sloan Alphabets on an electronic display at 20 feet. Objective and subjective refraction was done for every subject by the same optometrist. Oculyzer was used for the corneal topography map. Based on the corneal topography, location of the cone, and clinical signs on the slit lamp the severity of keratoconus was recorded. The patient was given a maximum of 20 mins for the adaptation with each lens tried. A minimum of 3 lens fittings were done for each patient. The sample size was taken 62 eyes of 31 infants. Subjects with Clinical signs of bilateral keratoconus, Aged between 15 to 50 years, Patients who were diagnosed for the first time with keratoconus, Patients who underwent the Contact lens trial for the first time were included and any other ocular pathology, Any Surgical interventions were excluded.

3. Results

There were a total of 31 patients (62 eyes) diagnosed with Bilateral Keratoconus based on clinical slit lamp findings and corneal topography at a tertiary eye hospital in the year 2021. It was found that 58.06% of the subjects were male and 41.94% of the subjects were females. The average age of the subjects was 20.4 years, 93.54% of the eyes were using spectacles whereas 6.54% of the eyes were not using any correction, and 25.80% of the subjects had a history of eye rubbing. Only 9.67% of the subjects reported a family history of Keratoconus. 74.1% of subjects had approached with the primary complaints of decreased vision whereas 19.5% of the subjects were referred to evaluate the ocular condition and for the opinion of correct diagnosis as they were unaware of their ocular condition and 6.4% of subjects with the complaint of frequent change of glasses.

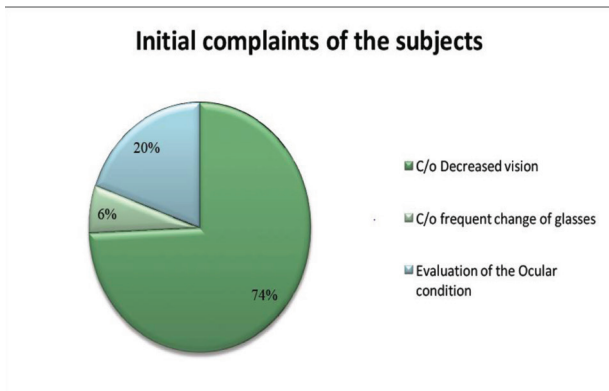


Figure-1: Showing initial complaints of the subjects.

79.03% of the eyes showed Scissors reflex on dry retinoscopy; whereas 9.67% had regular reflex and for 11.3% of the patients the reflex type was not mentioned.

3.1 Signs of Keratoconus

Depending on the slit lamp findings or signs observed in each eye that was diagnosed with Keratoconus the following are the results:-

Table1: Sign of keratoconus observed on slit lamp in percentage according to age.

| Signs observed on Slit lamp | %age |
|-----------------------------|--------|
| Ectasia | 87.09% |
| Apical Scarring | 3.22% |
| Vogt's Straie | 29.03% |
| Fleischer's ring | 61.29% |
| Munson's sign | 1.61% |

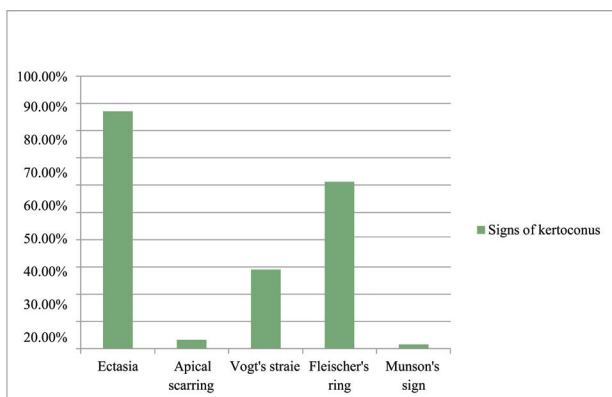


Figure-2: Showing signs of Keratoconus.

Corneal Ectasia is found to be the commonest sign of Keratoconus followed byFleischer's ring; Vogt straic and in advance cases apical scarring.

3.2 Corneal Topography

Based on the topographical signs the following observations were made:-

Table-2: Topography Finding.

| Topography Findings | Mean + SD |
|-------------------------|----------------|
| Front surface Flat K | 49.62 + 6.43 |
| Front Surface Steep K | 55.21 + 7.58 |
| Average Front surface K | 52.24 + 6.83 |
| Pachymetry at the Apex | 442.26 + 53.45 |
| Thinnest pachymetry | 426.42 + 55 |

3.3. Location of the Cone

It was found that 31 eyes had a centrally located cone; 17 eyes had an inferior cone and 14 eyes had an oblique bow tie pattern on the corneal topography map. None of the subjects had a superior or temporal cone. The mean refractive error was -5.47D + 4.51 (Mean + SD), 32 eyes were best corrected using Rose K lenses and 25 eyes with RGP lenses (Classic/ Purecon). Whereas 3 with piggy bag lenses and 2 with Mini sclera lenses. The majority of the eyes were best corrected with Rose K lenses followed by RGP (Classic/Purecon) lenses. A few were corrected with Piggy bag and advanced cases with Mini sclera lenses where RGP lenses failed to give an optimum fit. The mean unaided visual acuity was Log MAR value 0.93+0.43, the mean best corrected visual acuity with spectacles was Log MAR value 0.43+ 0.32. The above graph illustrates that there was a significant improvement in visual acuity when corrected with RGP/Rose K lenses. 62 out of 15 eyes underwent surgical interventions after 6-8 months of follow-up as the progression noted on the corneal topography map was more than 1.00 D in these eyes out of which 8 eyes underwent CXL; 4 eyes underwent DALK and 3 eyes underwent PK. Post-surgical intervention 11 out of 15 required RGP lenses for optical correction i.e. to get a better It was noted that all the subjects were best managed with Contact lens services and only 24.19% out of the total subjects underwent management with surgical options to halt the progression and further again managed with contact lenses post-surgical interventions.

4. Discussion

In the case of Keratoconus, the patients usually complain reduction in the quality of vision because of progressive thinning and bulging of the cornea (Pavlatos et al., 2020). The responsible factors for poor visual acuity are the irregularity of the front surface of the cornea with spectacle lenses. A satisfactory improvement in visual acuity was gained with the help of contact lenses instead of spectacle lenses as they mask the irregularity of the corneal surface (Mathan et al., 2020; Barbara et al., 2019). This is a multi-factorial condition that is associated genetically, biochemically, and biomechanically and also involves biological and environmental pathophysiological changes. This requires a multi-dimensional approach for appropriate early intervention and timely management by the concerned eye care professionals. (Pavlatos et al., 2020) This will further improve the quality of life among such individuals (Mathan et al., 2020). The primary form of vision correction for keratoconus patients is often through contact lenses. With expanding technology, the investigation of such ectatic conditions is simplified. These investigations often provide direction to the parameter selection of contact lenses. Corneal topography and anterior segment optical coherence tomography are a few technologies that are commonly used for managing such conditions. Based on the corneal topography and the location of the cone spectacles fail to correct the astigmatism of such eyes, hence RGP lenses are proven to correct astigmatism and give a better visual acuity (Patil et al., 2020). Spectacles and toric lenses are the first choices for early keratoconus management. With the emerging technology soft contact lenses are now available with aberration-controlled designs (Salem et al., 2019).

Whereas in the case of moderate to advance keratoconus rigid contact lenses are the first choice for management. In the cases of intolerance with the rigid lenses' patients can achieve desirable vision with hydrogel contact lenses, piggyback contact lenses, or scleral contact lenses (Otten et al., 2018; Efron, 2018). Recently CXL has become more common in patients with Keratoconus in tertiary eye care centers all across the globe. An ophthalmologist will consider CXL only if the progression of Keratoconus is rapid; whereas the practice of PK and DALK has reduced as various studies conclude (Chan, 2020; Lim & Lim, 2020). The surgical procedures known to reduce the progression of the keratoconus usually involve ultra-violet collagen cross-linking. This technique is based on UVA technology that crosses links between the corneal collagen fibrils which improves the rigidity of the cornea. Riboflavin is used as a catalyst that promotes stabilization and reduces the chances of reversal (Chan, 2020; Katsoulos et al., 2028). Contact lens management for keratoconus patients can be complex.

Modern contact lens materials and designs have improved clinical outcomes for this population of patients. In this course, an overall review can be made out as to decide upon the efficacy of the contact lenses as there is a wide spectrum of contact lens options and their applications in managing these irregular cornea patients (Musgrave et al., 2019).

Polymethyl methacrylate (PMMA) was the original contact lens material used in all contact lenses from the 1940s. Rigid gas-permeable contact lens materials have been available since the 1970s (Saraç et al., 2019; Gogri & Bhombal, 2020). The most commonly used lens design in patients with keratoconus is a single spherical base curve in rigid gas-permeable material. For patients with moderately advanced keratoconus who are unsuccessful with single-base curve lenses, multi-curve lenses can be successfully used. The Rose K lens is a relatively new system of multiple curves in the periphery to vary edge lift (Vincent & Fadel, 2019). In the case of advanced keratoconus usually, the contact lens fitting requires extra attention as it is complex to achieve the best and most reasonable lens centration. In such cases, the scleral contact lenses provide satisfactory outcomes with improved visual performance which further improves the quality of life of such patients. These lenses are imperative and offer satisfactory day-to-day needs of keratoconus patients. Hence the patient must be timely referred to a tertiary eye care center to cater to the need and requirements of the ectatic condition. The comprehensive eye examination to the detailed contact lens examination (trail, fitting and dispensing) may often delay the requirement et of surgical intervention for such patients (Jackson et al., 2019).

In present times because of the comfort over the cornea, the scleral lenses are the most effective and popular lenses that offer excellent vision in comparison to the previously available rigid gas permeable contact lenses. To prevent excessive hypoxia, the lens material used should provide high oxygen transmissibility (DK) (Salem & Solodovnikov, 2019; Jackson, 2019). Usually, contact lens wear is associated with intolerance and discomfort if proper care and regimen are not followed. This can also lead to corneal abrasions, ocular allergy, neovascularization, and many more. This retrospective study elicits the various practice patterns for the correction of an ectatic condition - Keratoconus which an optometrist and an ophthalmologist practice in a tertiary eye care center (Figure-2). The management of Keratoconus in tertiary eye care is a boon to the patients as they get exposed to all possible management options under the same roof. In a tertiary eye hospital, the practice of management of Keratoconus is a two-pronged approach; firstly, to correct the vision using non-surgical options and to note the progression of the disease every 4 to 6 months, secondly, if the progression is found to be rapid then the call for the surgical interventions is made by an ophthalmologist. Also, it is found that there is a

need for RGP CL to correct the residual corneal astigmatism post-surgery. According to the results, this retrospective study illustrates the dispensing of Rose K lenses in ocular condition-Keratoconus on the higher side; more or less equally to the practice of dispensing basic tricurve lenses (Classic RGP) and multi-curve lenses (Purecon) depending upon the severity of the disease and location of the cone. On the other hand, Piggyback lenses were dispensed to patients who aim for comfort as their primary need; whereas Hybrid lenses are not much in the picture because of the limited availability. Moving on to the advanced level of Keratoconus contact lenses practice shifts to Mini scleral or scleral lenses if the RGP lens fails to give a good fit. Out of the total population, only 24.19% of the patients were noted to have a significant 1.00D of progression on corneal topography map in 6-8 months who were then considered for surgical interventions, and based on pachymetry, the type of surgical intervention was decided. The need for RGP lenses post-surgical intervention were required in 73.33% of the population.

Limitation of the study: As it is a retrospective study much of the data which should be asked directly to the patient was not appropriately documented; which might have created a false value. The sample size of the study was less in number to set standards for the contact lens practice in a tertiary eye care center, in India.

5. Conclusion

The study concludes that male patients are predominant and the mean age of the keratoconus cases reported is 20.9+6.86. Also, eye rubbing is noted to be one of the factors contributing factor to this condition (25.80%). Considering the best corrected visual acuity the RGP lenses are proven to give the best vision to patients with Keratoconus. The management of Keratoconus patients in a tertiary eye care center is a multidisciplinary approach that includes the management of the patients by an optometrist and an ophthalmologist together. The efficacy of these lenses in terms of vision is highly adequate whereas a little compromised in terms of comfort if compared initially, but compliance increases as the subjects become habituated to the lens wear. Among patients with keratoconus, contact lens care is complex and involves time. This is challenging initially for both patients as well as practitioners. Advanced contact lenses such as rigid gas permeable lenses, scleral lenses, hybrid lenses, and piggy bag lenses provide restored vision to such individuals. Because of the above options, the need for surgical management reduces which is depicted in the above study.

6. Competing Interests

Authors declare no conflict of interest

References

- Assadpour, M., Nabovati, P., Hashemi, H., Rafati, S., Yekta, A., Jafarzadehpur, E., & Khabazkhoob, M. (2020). Comparison of corneal higher-order aberrations between miniscleral and hybrid lenses in keratoconus. *Optometry and Vision Science, 97*(9), 749-753.
- Athreya, P. K. (2018). Recent Advancements in Corneal Ectatic Conditions and their Management: A Mini Review. *J Ocul Infect Inflamm, 2*(101), 2.
- Barbara, R., Turnbull, A. M., Malem, A., Anderson, D. F., Hossain, P., Konstantopoulos, A., & Barbara, A. (2019). Epidemiology of keratoconus. *Controversies in the Management of Keratoconus*, 1-16.
- Chan, C. (2020). Corneal cross-linking for keratoconus: current knowledge and practice and future trends. *The Asia-Pacific Journal of Ophthalmology, 9*(6), 557-564.
- Efron, N. (2018). *Contact Lens Complications E-Book*. Elsevier Health Sciences.
- Fan, R., Chan, T. C., Prakash, G., & Jhanji, V. (2018). Applications of corneal topography and tomography: a review. *Clinical & experimental ophthalmology, 46*(2), 133-146.
- Gogri, P., & Bhombal, F. A. (2020). A new technique for fitting of tricurve rigid gas-permeable contact lens in penetrating keratoplasty eyes using Scheimpflug imaging. *Indian Journal of Ophthalmology, 68*(6), 1057.
- Gustafsson, I., Bergström, A., Myers, A. C., Ivarsen, A., & Hjortdal, J. (2020). Association between keratoconus disease severity and repeatability in measurements of parameters for the assessment of progressive disease. *PLoS One, 15*(2), e0228992.
- Jackson, T. L. (Ed.). (2019). *Moorfields manual of ophthalmology*. JP Medical Ltd.
- Katsoulos, K., Rallatos, G. L., & Mavrikakis, I. (2018). Scleral contact lenses for the management of complicated ptosis. *Orbit, 37*(3), 201-207.
- Lim, L., & Lim, E. W. L. (2020). Current perspectives in the management of keratoconus with contact lenses. *Eye, 34*(12), 2175-2196.
- Mahmoud, M. E. A., Hamza, I. E., Assaf, A. H., & Eliwa, T. F. (2018). Posterior corneal astigmatism changes in cases with keratoconus. *The Egyptian Journal of Hospital Medicine, 72*(10), 5433-5437.
- Mathan, J. J., Gokul, A., Simkin, S. K., Meyer, J. J., Patel, D. V., & McGhee, C. N. (2020). Topographic screening reveals keratoconus to be extremely common in Down syndrome. *Clinical & Experimental Ophthalmology, 48*(9), 1160-1167.

- Musgrave, C. S. A., & Fang, F. (2019). Contact lens materials: a materials science perspective. *Materials*, 12(2), 261.
- Olivo-Payne, A., Abdala-Figuerola, A., Hernandez-Bogantes, E., Pedro-Aguilar, L., Chan, E., & Godefrooij, D. (2019). Optimal management of pediatric keratoconus: challenges and solutions. *Clinical ophthalmology*, 1183-1191.
- Otten, H. M., van der Linden, B. J., & Visser, E. S. (2018). Clinical performance of a new bitangential mini-scleral lens. *Optometry and Vision Science*, 95(6), 515-522.
- Patil, M., & Mehta, J. S. (2020). Lamellar keratoplasty for advanced keratoconus. *The Asia-Pacific Journal of Ophthalmology*, 9(6), 580-588.
- Pavlatos, E., Chen, S., Yang, Y., Wang, Q., Huang, D., & Li, Y. (2020). A coincident thinning index for keratoconus identification using OCT pachymetry and epithelial thickness maps. *Journal of Refractive Surgery*, 36(11), 757-765.
- Majumdar, A. Genetics and Keratoconus.
- Roongpoovapatr, V., Abou Shousha, M., & Charukamnoetkanok, P. (2020). Keratoconus Treatment Toolbox: An Update. In *Eyesight and Imaging-Advances and New Perspectives*. IntechOpen.
- Rubinfeld, R. S., Caruso, C., & Ostacolo, C. (2019). Corneal cross-linking: the science beyond the myths and misconceptions. *Cornea*, 38(6), 780-790.
- Salem, B. R., & Solodovnikov, V. I. (2019). Decision support system for an early-stage keratoconus diagnosis. In *Journal of Physics: Conference Series* 1419(1), 12-23.
- Saraç, Ö., Kars, M. E., Temel, B., & Çağıl, N. (2019). Clinical evaluation of different types of contact lenses in keratoconus management. *Contact Lens and Anterior Eye*, 42(5), 482-486.
- Şengör, T., & Kurna, S. A. (2020). Update on contact lens treatment of keratoconus. *Turkish Journal of Ophthalmology*, 50(4), 234.
- Shehata, A. E., Foster, J. W., Jun, A. S., & Soiberman, U. S. (2020). The correlation between corneal findings and disease severity in keratoconus per Scheimpflug corneal tomography. *Journal of Ophthalmology*, 2020.
- Toprak, I., Cavas, F., Velazquez, J. S., Alio del Barrio, J. L., & Alio, J. L. (2020). Subclinical keratoconus detection with three-dimensional (3-D) morphogeometric and volumetric analysis. *Acta Ophthalmologica*, 98(8), e933-e942.
- Vincent, S. J., & Fadel, D. (2019). Optical considerations for scleral contact lenses: A review. *Contact Lens and Anterior Eye*, 42(6), 598-613.



Journal of Multidisciplinary Research in Healthcare

Chitkara University, Saraswati Kendra, SCO 160-161, Sector 9-C, Chandigarh, 160009, India

Volume 8, Issue 2

April 2022

ISSN 2393-8536

Copyright: [© 2022 Nayan Gupta, Astha Mishra, Shankar Mehra] This is an Open Access article published in Journal of Multidisciplinary Research in Healthcare (J. Multidiscip. Res. Healthcare) by Chitkara University Publications. It is published with a Creative Commons Attribution-CC-BY 4.0 International License. This license permits unrestricted use, distribution, and reproduction in any medium, provided the original author and source are credited.
