

## Visumax Femtosecond Laser Impact on Myopic Residual Refractive Error

Kaushal Kishor Sahu<sup>1</sup>, Sachitanand Singh<sup>2\*</sup>  and Renu Thakur<sup>3</sup> 

<sup>1,2,3</sup>Chitkara School of Health Sciences, Chitkara University, Punjab

\*[sachitanand.singh@chitkara.edu.in](mailto:sachitanand.singh@chitkara.edu.in) (Corresponding Author)

### ARTICLE INFORMATION

#### Keywords:

Myopia, LASIK, PRK, ReLex, FLEEx, Refractive correction, Residual Refractive Error, SMILE Surgery

### ABSTRACT

**Background:** Compare the residual refractive power following “small incision lenticule extraction” (SMILE) surgical correction in myopic patients with moderate to severe myopia and myopic astigmatism.

**Aim:** To study the pre op with post op residual refractive status comparison in low to high myopia and myopic astigmatism patients under gone ReLex SMILE operation.

**Methods:** Prospective comparative analysis with 65 eyes of 33 patients classified into three groups: mild myopia –1.00 to –3.00 D, moderate myopia –3.25 to –6.00 D, and high myopia –6.25 to –10.00 D, comprising spherical and cylindrical using spherical equivalent (SE). Using the SMILE surgery, each patient were corrected for myopic refractive error. Retinoscope was conducted preoperatively and postoperatively one day and one month following surgery, respectively. Results: Pre op 1 day and 1 month are showing a significant and gradual decrease where low and high myopia are compared, which is statistically significant for both one day (0.007) and one month (0.001) post operatively, but low to moderate (0.282) and moderate to high (0.147) post operatively 1 day and 1 month it is not statistically significant. This indicates that high myopia has greater residual power than low and moderate myopia.

**Conclusion:** This research concludes that residual power increases as myopia increases in severity. As the objective residual power after SMILE surgery is less than  $\pm 0.50$ D in approximately 75% – 80% of eyes, SMILE surgery is a suitable alternative for refractive surgery correction with less complications than other refractive surgery techniques.

DOI: [10.15415/jmrh.2021.81002](https://doi.org/10.15415/jmrh.2021.81002)



## 1. Introduction

Small incision lenticule extraction (SMILE) is a new keratorefractive surgery technique for the correction of refractive errors like as myopia and myopic astigmatism (Sekundo *et al.*, 2011). SMILE is an innovative, precise, and convenient flapless laser eye surgery that is only achievable using the visumax femtosecond laser platform from Germany's Carl Zeiss (Shah *et al.*, 2011). No other laser device now permits this treatment to be conducted. Visumax femtosecond laser is the most advanced laser technology in over a decade. It can cure myopia and myopic astigmatism without any of the safety issues associated with conventional vision correction techniques, and it provides even greater comfort and maybe greater precision. Refractive lenticule extraction (ReLex) SMILE is an FDA approved procedure that takes only 23 seconds per eye and is minimally invasive, flap-free, and blade-free, with minimum discomfort and rapid recovery (Ramirez-Miranda *et al.*, 2013). With the aid of refractive lenticule extraction (ReLex) SMILE, myopia of –1.00 D to –10.00 D and myopic astigmatism of –5.00 D

can be treated (Berkowitz, 2017). This study aimed to assess pre and post operative residual refractive state in individuals with mild to high myopia and myopic astigmatism who had had the ReLex SMILE operation.

## 2. Material & Methodology

33 subjects were included in this present study after sample size calculation and here convenient sampling technique used to collect the sample (Naing *et al.*, 2006). Subject were enrolled in this study after informed consent and ethical clearance was opted from the institutional ethical committees. Preoperative Refraction was done with the help of Retinoscope (Heine) and Retinoscopy power was categorised (Ganesh *et al.*, 2015). Low myopia has a sphere equivalent power between –1 and –3, whereas moderate myopia had a spherical equivalent power between –3.25 and –6. and high myopia spherical equivalent power range from –6.25 to –10.00D. Topography (ATLAS 9000 Corneal Topography System) was done for corneal mapping. Optical Coherence Tomography (Visante OCT) was done

for anterior and posterior corneal imaging and Pachymetry, this has helped in patient selection for surgery. After all the clinical checkup Patients were gone under surgery. Following industry guidelines, one ophthalmologist carried out all procedures using the same technique. For SMILE surgery, a 140nJ VisuMax femtosecond laser (Carl Zeiss Meditec) was utilised. The diameter of the lenticule was always between 6.0 and 6.6 mm, and the thickness varied based on the refractive power that needed to be adjusted. The cap's diameter was between 7.0 and 7.5 mm, and its thickness was 120 microns. Postoperative follow-up appointments are held, post op 1 day and 1 month. At each follow-up appointment, Retinoscopy was done to find out the residual power for compare between them on the basis of power.

### 3. Results

Sixty-five eyes of 33 patients were treated. Mean age was 26.68 (range 19 to 38 years), 12 were male and 21 were female and Standard deviation was  $\pm 5.05$ . Follow-up time was day 1 and 1 month. With mean age of  $26.68 \pm 5.05$  [19-38 years]. Sixty-five eyes were treated where Low myopia is 20 (30.77%), Moderate myopia is 28 (43.08%) and High myopia is 17 (26.15%). Mean standard deviation (Mean  $\pm$  SD) of preoperative low and high myopia spherical equivalent (SE) is  $-2.23 \pm 0.63$  and  $-7.34 \pm 0.43$  respectively. After comparison between both low and high preoperative myopia are showing statistically significant where,  $P < 0.001$ . Mean  $\pm$  SD of low and high myopia SE is  $-0.19 \pm 0.31$  and  $-0.62 \pm 0.42$  respectively at 1 day post op. After comparison both low and high myopia are showing statistically significant where  $P = 0.007$ . Mean standard deviation of preoperative low and moderate myopia spherical equivalent is  $-2.23 \pm 0.63$  and  $-4.52 \pm 0.86$  respectively.

**Table-1:** Follow up after 1 Day.

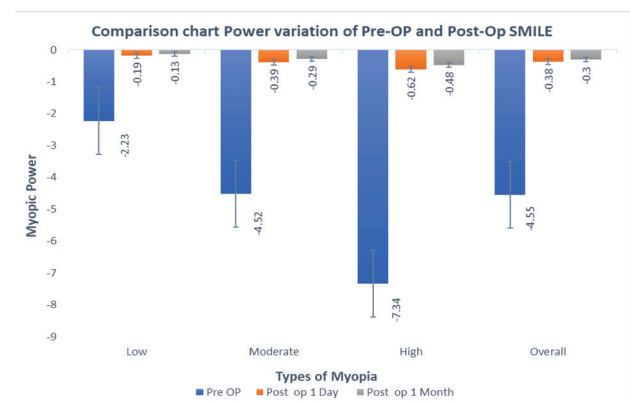
	Pre-OP		Postp op 1 Day	
	Mean $\pm$ SD	P-Value	Mean $\pm$ SD	P-Value
<b>Low</b>	$-2.23 \pm 0.63$	$<0.001$	$-0.19 \pm 0.31$	0.007
<b>Moderate</b>	$-4.52 \pm 0.86$	$<0.001$	$-0.39 \pm 0.47$	0.282
<b>High</b>	$-7.34 \pm 0.43$	$<0.001$	$-0.62 \pm 0.42$	0.244
<b>Overall</b>	$-4.55 \pm 2.06$	$<0.001$	$-0.38 \pm 0.44$	0.010

After comparison between both low and moderate preoperative myopia are showing statistically significant where,  $P < 0.001$ . Mean  $\pm$  SD of low and moderate myopia SE is  $-0.19 \pm 0.31$  and  $-0.39 \pm 0.47$  respectively at 1 day post op. After comparison both low and moderate myopia are not showing statistically significant where  $P$

0.282. Mean  $\pm$  SD of preoperative moderate and high myopia spherical equivalent (SE) is  $-4.52 \pm 0.86$  and  $-7.34 \pm 0.43$  respectively. After comparison between both low and high preoperative myopia are showing statistically significant where,  $P < 0.001$ . Mean  $\pm$  SD of moderate and high myopia SE is  $-0.39 \pm 0.47$  and  $-0.62 \pm 0.42$  respectively at 1 day post op. After comparison both moderate and high myopia are not showing statistically significant where  $P$  was 0.244.

**Table-2:** Follow up after 1 Month.

	Pre-OP		Post-Op 1 Month	
	Mean $\pm$ SD	P-Value	Mean $\pm$ SD	P-Value
<b>Low</b>	$-2.23 \pm 0.63$	$<0.001$	$-0.13 \pm 0.22$	0.001
<b>Moderate</b>	$-4.52 \pm 0.86$	$<0.001$	$-0.29 \pm 0.28$	0.147
<b>High</b>	$-7.34 \pm 0.43$	$<0.001$	$-0.48 \pm 0.34$	0.114
<b>Overall</b>	$-4.55 \pm 2.06$	$<0.001$	$-0.30 \pm 0.31$	0.002



**Figure 1:** Shows the comparison in dioptics power of the preop before SMILE surgery, post op 1 day and post op 1 month after the SMILE surgery in low, moderate, high and overall myopia. Here in all the category pre-op myopia power has higher and post op 1 day has lower power and post op 1 month has the lowest power.

### 4. Discussion

In the present study, a comparison is made between low to high myopia and myopic astigmatism before and after surgery. Follow up 1 day and 1 month compared spherical equivalent where it is significantly and progressively decreased and comparison 1 day and 1 month low to high is showing statistically significant but comparison 1 day and 1 month low to moderate and moderate to high post op are showing not significant where among of all 3 group high myopia showing more residual power and This research demonstrates excellent refractive prediction, with 76.92% of eyes achieving a residual refractive power after surgery. In a previous research, 82% of eyes achieved a residual post-operative refractive error within

+/- 0.50D of the goal after three months (Recchioni *et al.*, 2018). According to Kamiya *et al.* (2015), 77 percent -100 percent and 94.2 percent -100 percent of eyes were within +/- 0.50D and +/-1.00D, respectively. In terms of the spherical equivalent, a previous study by Wu *et al.* (2016) revealed that high myopic eyes experienced significant regression, whereas low and moderate myopic eyes did not. The current study demonstrates that low and moderate myopia are more susceptible to post-operative refractive error than high myopia (Verdaguer *et al.*, 2013). Three months after surgery, 86.84 percent of patients had UCVA >20/20. SMILE is emerging as a novel technique that eliminates LASIK's adverse effects. Thus, being painless and flap less treatment with high refractive accuracy and predictability, and quicker recovery with superior patient comfort. As a refractive surgery to address myopia and myopic astigmatism, SMILE is better than LASIK. We may thus conclude that the refractive result of SMILE surgery is good for myopic refractive error (Teus *et al.*, 2014; Yang *et al.*, 2020).

## 5. Conclusion

This study concludes that residual power is increasing as degree of myopia increasing. As Smile gives objectively residual power smaller than +/-0.50D, in all most 75 percent -80 percent of eyes. Smile can consider as one of good alternative of refractive surgery where all the complication is extremely minimal than other refractive surgery approach.

## 6. Ethical Declaration

Ethical clearance taken from the institutions, Hospital and from each patient before taking them as a participant in the study, There no conflict of interest

## 7. Acknowledgment

Mr. Aditya Goyal, Mr. Diwakar Rao, Mr. Tapas Kumar De, Mrs. Namratha Hedge, Dr. Preethi Pradhan, Dr. Rajesh B.T.J, Dr. Bindiya Hapani and Mr Harrish h

## 8. Funding

No funding was taken for this research

## References

- Berkowitz, R. (2017). Enhancing vision: Rachel Berkowitz reports on how laser-based systems are advancing vision correction surgeries. *Electro Optics*, (276), 18-23.
- Ganesh, S., Patel, U., & Brar, S. (2015). Posterior corneal curvature changes following refractive small incision lenticule extraction. *Clinical Ophthalmology*, 1359-1364.
- Kamiya, K., Shimizu, K., Igarashi, A., & Kobashi, H. (2015). Visual and refractive outcomes of small incision lenticule extraction for the correction of myopia: 1-year follow-up. *BMJ open*, 5(11), e008268.
- Naing, L., Winn, T. B. N. R., & Rusli, B. N. (2006). Practical issues in calculating the sample size for prevalence studies. *Archives of orofacial Sciences*, 1, 9-14.
- Ramirez-Miranda, A., Navas, A., De La Mota, A., Ramirez-Luquín, T., & Graue-Hernández, E. (2013). Small Incision Lenticule Extraction (SMILE) procedure for the correction of myopia and myopic astigmatism: What we have learned after 120 eyes in 1 year. *Investigative Ophthalmology & Visual Science*, 54(15), 3712-3712.
- Recchioni, A., Hartwig, A., Dermott, J., Vaswani, S., Bhatt, J., Morris, R., & O'donnell, C. (2018). Early clinical outcomes after small incision lenticule extraction surgery (SMILE). *Contact Lens and Anterior Eye*, 41(1), 132-135.
- Sekundo, W., Kunert, K. S., & Blum, M. (2011). Small incision corneal refractive surgery using the small incision lenticule extraction (SMILE) procedure for the correction of myopia and myopic astigmatism: results of a 6 month prospective study. *British Journal of Ophthalmology*, 95(3), 335-339.
- Shah, R., Shah, S., & Sengupta, S. (2011). Results of small incision lenticule extraction: all-in-one femtosecond laser refractive surgery. *Journal of Cataract & Refractive Surgery*, 37(1), 127-137.
- Teus, M. A., & Garcia-Gonzalez, M. (2014). Comparison of the visual results after small incision lenticule extraction and femtosecond laser-assisted LASIK for myopia. *Journal of Refractive Surgery*, 30(9), 582-582.
- Verdaguer, P., El-Husseiny, M. A., Amat, D. E., Castellón, O. G., Manero, F., Pérez, M. B., & Villanueva, J. L. G. (2013). Small incision lenticule extraction (SMILE) procedure for the correction of myopia and myopic astigmatism. *Journal of Emmetropia: Journal of Cataract, Refractive and Corneal Surgery*, 4(4), 191-196.
- Wu, W., Wang, Y., Zhang, H., Zhang, J., Li, H., & Dou, R. (2016). One-year visual outcome of small incision lenticule extraction (SMILE) surgery in high myopic eyes: retrospective cohort study. *BMJ open*, 6(9), e010993.
- Yang, W., Liu, S., Li, M., Shen, Y., & Zhou, X. (2020). Visual outcomes after small incision lenticule extraction and femtosecond laser-assisted LASIK for high myopia. *Ophthalmic Research*, 63(4), 427-433.



## Journal of Multidisciplinary Research in Healthcare

---

Chitkara University, Saraswati Kendra, SCO 160-161, Sector 9-C,  
Chandigarh, 160009, India

---

**Volume 8, Issue 1**

**Ocoteber 2021**

**ISSN 2393-8536**

---

Copyright: [© 2021 Kaushal Kishor Sahu, Sachitanand Singh and Renu Thakur] This is an Open Access article published in Journal of Multidisciplinary Research in Healthcare (J. Multidiscip. Res. Healthcare) by Chitkara University Publications. It is published with a Creative Commons Attribution- CC-BY 4.0 International License. This license permits unrestricted use, distribution, and reproduction in any medium, provided the original author and source are credited.

---